Diagnosing mantle cell lymphoma in your patients

A diagnosis of MCL can involve several stages and a range of investigative procedures. This page will explore these stages in more detail.

Diagnosing mantle cell lymphoma (MCL)

MCL is diagnosed based upon detailed patient history, thorough clinical evaluation and a variety of specialised tests, including a biopsy of an affected lymph node or the bone marrow.[1] Such testing is necessary to[1]:

Confirm the specific type (and subtype) of NHL present
Assess the nature and extent of the disease
Determine the most appropriate treatments

Risk stratification and prognosis in patients

Because treatment may differ depending on disease stage, in-depth evaluation should occur at initial staging.[2,3]

The risk assessment can help plan the next steps for treatment of MCL by dividing it into[2,3]:

• Indolent disease – watch and wait

OR

• Aggressive disease – active treatment

MIPI

A way to predict the outlook for patients with MCL was developed – The Mantle Cell International Prognostic Index (MIPI). It is a classification tool that enables patients to be grouped as low, medium or high risk.[4,5]

Probability of overall survival (OS) over time in MCL patients based on the MIPI risk stratification[4]

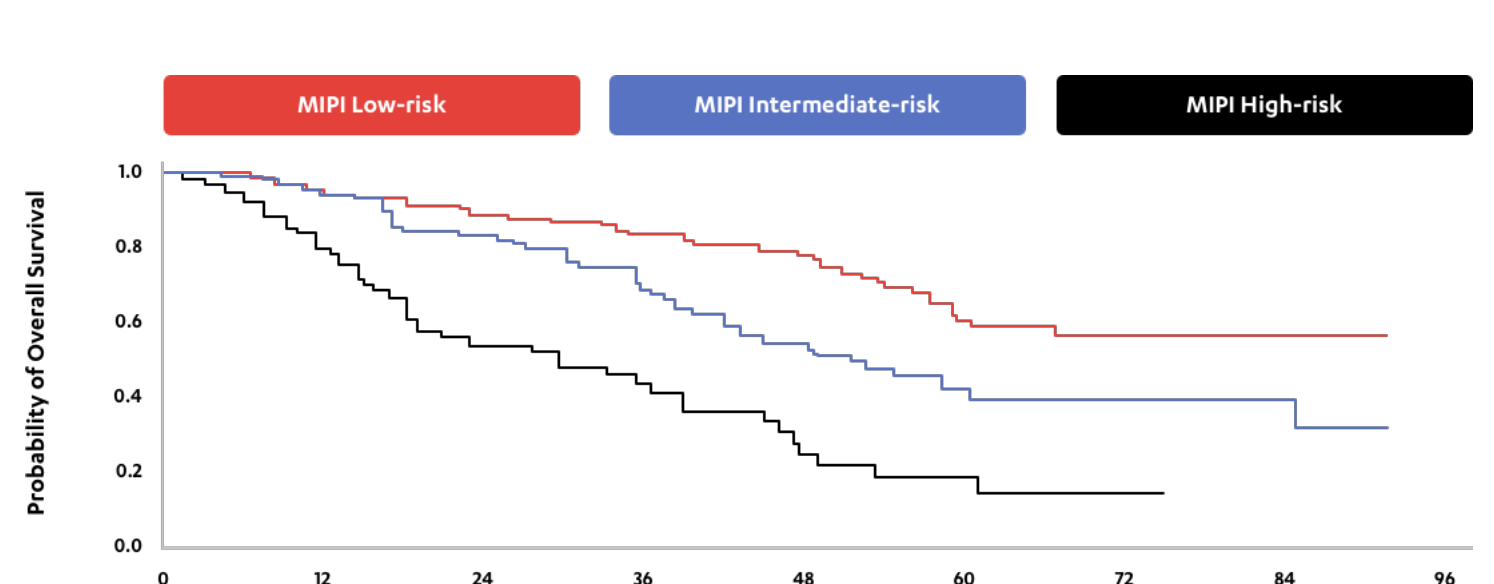

Adapted from Vose *et al.* 2017.

The independent prognostic factors for shorter OS identified by MIPI were higher age, worse ECOG performance status, higher LDH, and a higher white blood cell count at diagnosis.[4,5]

Simplified MIPI Prognostic Index[4]

Points	Age (years)	ECOG PS	LDH/ULN LDH	WBC 10^9/L
0	<50	0–1	<0.67	<6.700
1	50–59	–	0.67–0.99	6.700–9.999
2	60–69	2–4	1.00–1.49	10.000–14.999
3	70	–	1.500	15.000

For each prognostic factor, 0–3 points were given to each patient to a maximum of 11.

• Patients with 0–3 points in total were classified as low-risk, patients with 4–5 points as intermediate-risk, and patients with 6–11 points as high-risk
• ECOG PS was weighted with 2 points if patients were unable to work or bedridden (ECOG PS 2–4)

Ki-67 index

Another strong predictor for the survival of patients with MCL is the Ki-67 proliferation index.[6] It is the most important prognostic factor used in routine clinical practice.[7] Ki-67 is a protein linked to cell proliferation, thus measuring Ki-67 provides an indication on the rate of cellular growth.[8] The Ki-67 proliferation index is the percentage of mantle cell lymphoma cells that express Ki-67.[9]

Ki-67 proliferation index (%)[9]	Median survival (months)[9]
<10	42
10–40	30
>40	15

The Ki-67 proliferation index is the % of mantle cell lymphoma cells that express Ki-67.[9]

MIPI-c

MIPI and Ki-67 can be combined to create the combined MIPI (MIPI-c).[4] The MIPI-c provides a more accurate representation of the predicted survival for patients with MCL compared with MIPI and divides patients into four groups: low, low-intermediate, high-intermediate or high risk.[7]

MIPI and Ki-67 index in MIPI-c classification[2]

MIPI risk group (weights in MIPI-c)	Ki-67 index (weight in MIPI-c)	MIPI-c risk group (sum of weights)
Low (0)	<30% (0)	Low (0)
Low (0)	≥30% (1)	Low-intermediate (1)
Intermediate (1)	<30% (0)	Low-intermediate (1)
Intermediate (1)	≥30% (1)	High-intermediate (2)
High (2)	<30% (0)	High-intermediate (2)
High (2)	≥30% (1)	High (3)

Clinical and molecular characteristics predict outcomes in MCL patients[10,11]

OS stratified by MIPI-c in the European MCL younger/MCL elderly cohort[10]

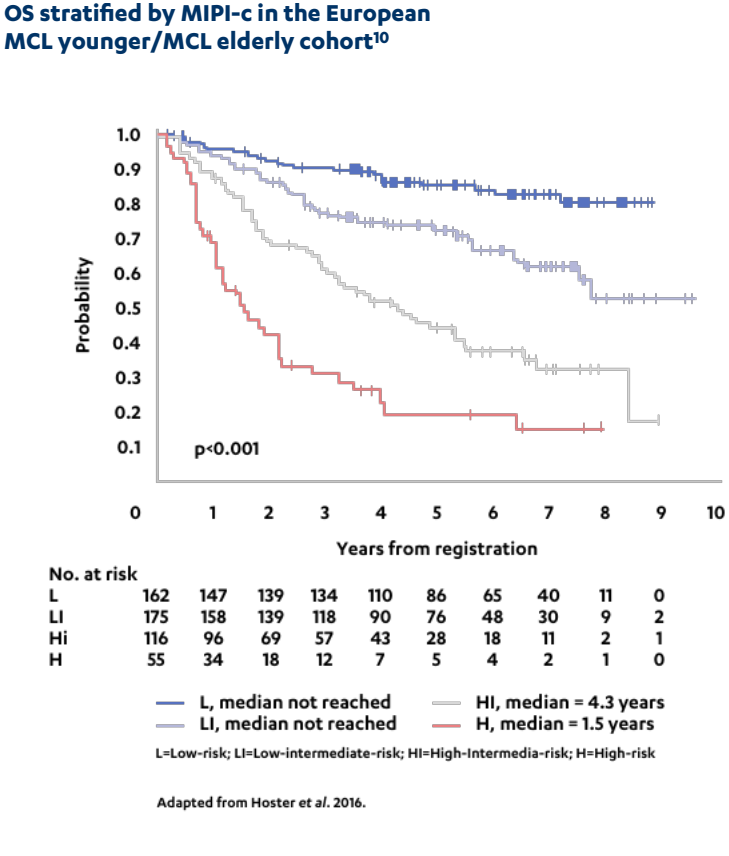

Adapted from Hoster *et al.* 2016.

OS according to Ki-67 index[10]

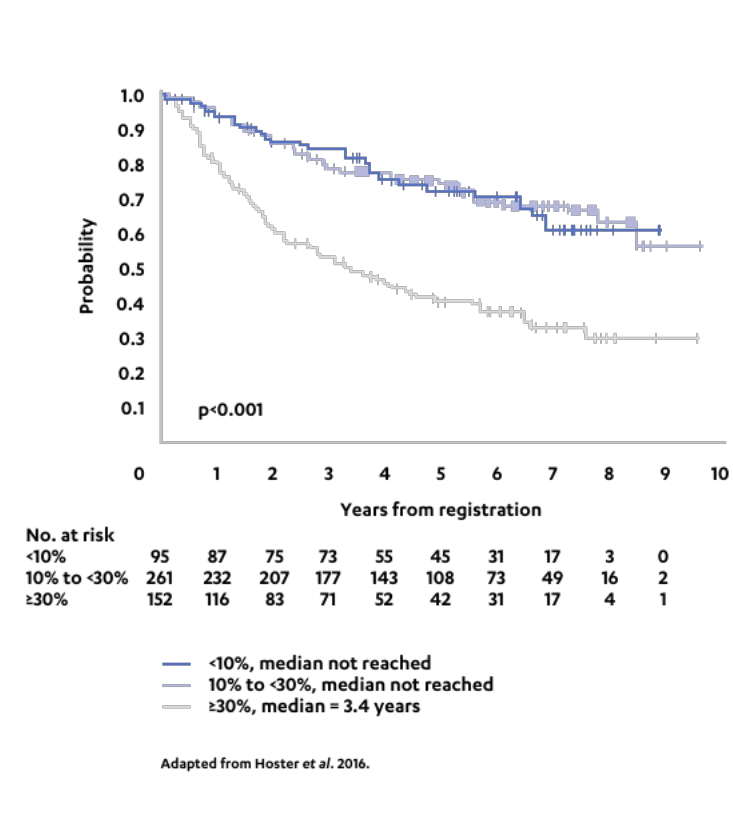

Adapted from Hoster *et al.* 2016.

OS according to blastoid vs non-blastoid cytology[10]

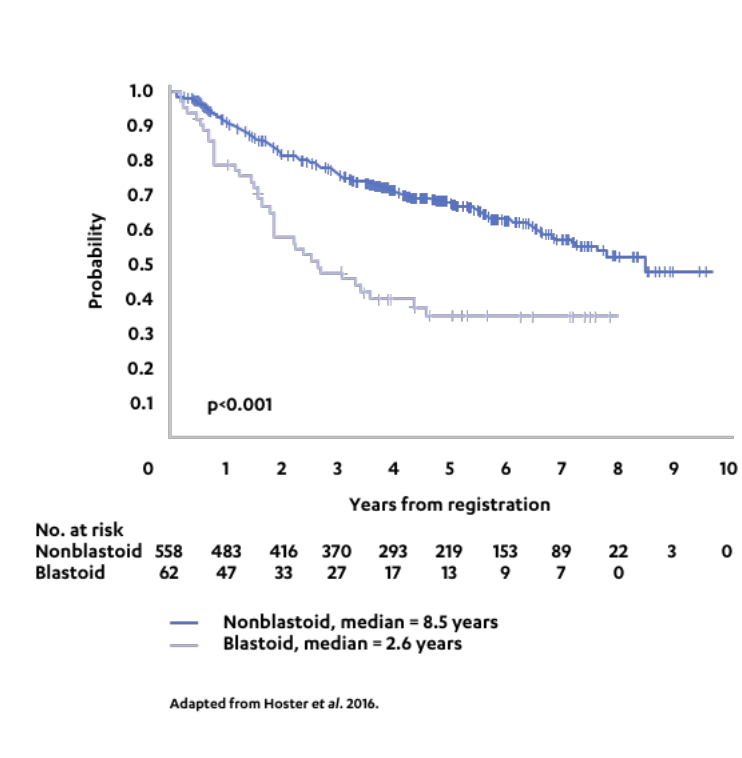

Adapted from Hoster *et al.* 2016.

Estimate of OS with or without TP53 deletions and mutations[11]

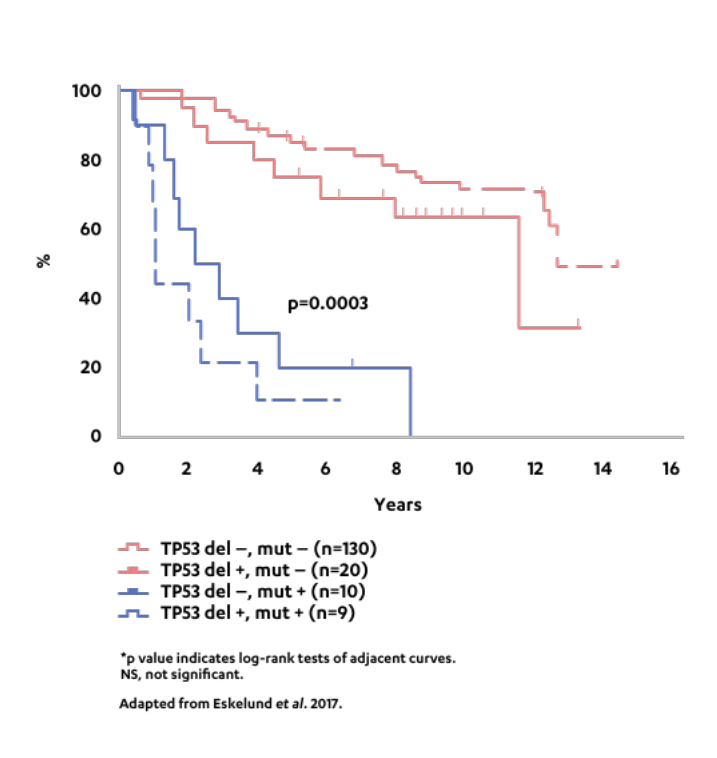

Adapted from Eskelund *et al.* 2017.

Types of mantle cell lymphoma

For treatment purposes, MCL has been categorised into two major subgroups, which were included in the WHO 2016 update of lymphoid malignancies.[12] The subgroups of MCL are distinct in clinical presentation and molecular features.[12]

- **Conventional MCL (70–80% of MCL cases)[3]**
  Symptomatic lymph adenopathy or symptomatic extra-nodal disease requiring systemic therapy. It is typically seen in 70–80% of patients with MCL.[3] This is a bulky nodal/extranodal variant with an aggressive disease course.[3]
- **Smouldering nodal/extra-nodal MCL and asymptomatic purely leukaemic non-blastoid MCL (10–20% of MCL cases)[3]**
  Given that standard therapy does not appear to cure MCL, a 'watch and wait' strategy for elderly patients and those with asymptomatic or low MIPI MCL should be considered.[3] It is typically seen in 10–20% of patients with MCL.[3] In most cases, this type is generally associated with an indolent disease course and superior outcome.[3]
- **In situ MCL**
  In situ MCL is rare and is characterised by the presence of CD5+ and cyclinD1+ small lymphocytes in the mantle zone of the follicle in a morphologically reactive lymph node.[7,12,13] Currently, patients with in situ MCL are monitored with a 'watch and wait' approach.[14]

Symptoms of mantle cell lymphoma

Patients with MCL may initially present in a primary care setting with persistent but non-specific symptoms, including swelling of lymph nodes, unintentional weight loss or night sweats.[3] It should be noted that asymptomatic presentation accounts for around 10–20% of MCL cases.[3]

At this stage, the primary care physician should take the patient's medical history, perform a physical examination and request initial blood tests, including complete blood count and blood film.[3,7] If lymphoma is suspected, a referral will then be made.

Symptoms to note include[6]:

Fever
Fatigue
Itching
Enlarged spleen
Bleeding
Hepatomegaly
Abdominal pain
Atypical lymphocytes
CNS involvement
Night sweats
Unintentional weight loss

Diagnostic pathway

Confirming a diagnosis of MCL can involve several steps and a series of investigative tests.[2-4]

Primary care[3,7]

Palpable lymph nodes
Blood analyses (CBC with differential, blood smear) showing abnormal cytomorphology

↓

Specialist testing[2,7,15]

Essential:
– Surgical specimen, preferably a lymph node biopsy
– Immunohistochemistry and cytology: CD5/10/19/20/23, BCL2/6, cyclin D1, Ki-67
Useful in certain circumstances:
a. Radiology testing
– CT scan (neck, thorax, abdominal, pelvic)
b. In leukaemic cases
– Bone marrow biopsy: FACS (CD5/19/20Þ) and FISH t(11;14), t(14;18)
– LDH
– Uric acid
– Liver function
– Renal function
c. If indolent disease considered: SOX11 or IGHV

↓

Evaluation[2,7,15]

Specialist determines prognosis using MIPI-c
Watch and wait
Start treatment

↓

First-line therapy choice[2,7,15]

Regimen chosen based on the nature of the lymphoma, patient age, physical fitness and local/national/international guidelines

Mantle cell lymphoma diagnostic test

To confirm an MCL diagnosis, a biopsy or analysis of a sample may undergo a few tests.[4,7]

A biopsy or sample can be taken from[4,7]:

An involved lymph node or extranodal site (e.g., the colon, stomach or salivary gland)
Bone marrow
Peripheral blood in cases where malignant B cells are present in the circulation

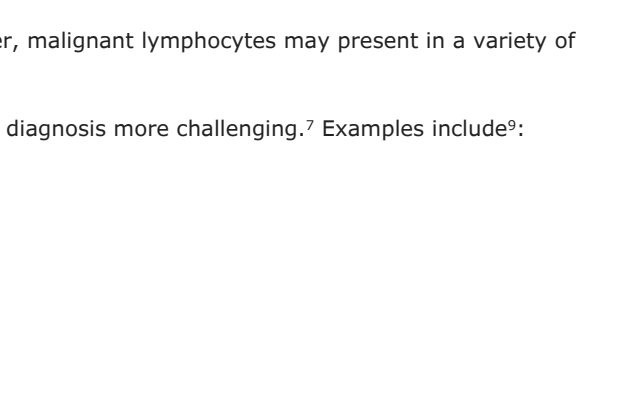

Microscopic examination

Microscopic examination of involved lymph node or tissue is a key part of the diagnosis of MCL.

A diagnosis of MCL requires histopathological confirmation of lymph node infiltration. A part, or all, of an easily accessible, enlarged lymph node is removed.[2]

The histological report should give the diagnosis according to the WHO classification and Ki-67, a proliferation marker, the most established histomorphological risk factor.[2]

Most tumours have a classic structure of small-medium sized cells with irregular nuclei. However, malignant lymphocytes may present in a variety of forms.[2]

In some cases, MCL cells can resemble other forms of B-cell malignancy in appearance, making diagnosis more challenging.[7] Examples include[9]:
A small cell variant (3.6% of cases)
A blastoid variant (2.6% cases)
A pleomorphic variant (5.9% cases)

Immunophenotypic evaluation

One way to aid in the accurate diagnosis of B-cell malignancy is immunophenotyping.[2]

Immunophenotyping using flow cytometry has become an integral part in the subclassification of B-cell lymphomas.[16]

MCL has a characteristic immunophenotype that is distinct from other B-cell malignancies.[7] The presence of cyclin D1 is particularly important, as research has shown that almost all cases of MCL are positive for this protein.[7]

Genetic testing

A specific cytogenetic abnormality found in almost all patients with MCL is the translocation t(11;14).[4,6,7] This causes lymphoma cells to overexpress cyclin D1, a contributor to uncontrolled growth.7 Cyclin D1 is not expressed by healthy B-cells.[4,7]

Other genetic mutations can be markers for MCL subtypes – e.g., TP53 mutations and p16 deletions are linked to aggressive disease.[4]

Clinical presentation

MCL subtype	Clinical features[3]
Conventional MCL	Symptomatic bulky/nodal/extra-nodal disease Classic or blastoid/pleomorphic cytomorphology Signs of clinical progression
Smouldering nodal/extra-nodal MCL	Lack of B symptoms (drenching night sweats, unintentional weight loss in ≤6 months of >10% of normal body weight, fever >38°C) Normal serum LDH, β-2 microglobin levels WBC <30,000 x 109/L Low MIPI score Ki-67 ≤30% on lymphoma cells in non-marrow tissue biopsy Non-blastoid pleomorphic cytomorphologic pattern in tissue biopsy Max lymph node diameter <3 cm, spleen size <20 cm PET scan showing the maximum SUV <6 DNA sequencing lacks TP53 or NOTCH1/2 mutations FISH testing shows no deletion 17p or MYC translocation and an absence of complex karyotype
Asymptomatic purely leukaemic non-blastoid MCL	Monoclonal B lymphocytosis (with MCL immunophenotype and non-blastoid morphology) in peripheral blood or in bone marrow with/without splenomegaly

ESMO guideline recommendations[2]

Diagnosis should be based on a surgical specimen, preferably a lymph node biopsy. Core biopsies should only be carried out in patients without easily accessible lymph nodes (e.g. retroperitoneal bulk), keeping in mind the heterogeneity of MCL.

In rare cases with leukaemic manifestation only, a bone marrow biopsy may be sufficient if additional diagnostic measures are applied, immunophenotype (CD5+, CD19/20+), detection of t(11;14)(q13;q32) and overexpression of cyclin D1. Fine needle aspirations are inappropriate for a reliable evaluation of additional risk factors (cytology, cell proliferation).

A histological report should give the diagnosis according to the WHO classification and Ki-67 as the most established histomorphological risk factor.

Most tumours have a classic morphology of small-medium sized cells with irregular nuclei. However, the malignant lymphocytes may present with a spectrum of morphological variants, including small round (resembling chronic lymphocytic leukaemia), marginal zone-like, pleomorphic and blastoid cells.

In the updated WHO classification, a leukaemic non-nodal subtype has been characterised based on the clinical presentation usually with a more indolent clinical course. As only the minority of these cases is correctly diagnosed based on classical histology only, review by an expert haematopathologist is advised. In particular, additional immunohistochemistry for detection of cyclin D1 overexpression is mandatory.

In the rare cyclin D1–negative cases, detection of SOX11 may help to establish the diagnosis.

CBC=complete blood count; CT=computerised tomography; DNA=deoxyribonucleic acid; ECOG=Eastern Cooperative Oncology Group; ESMO=European Society for Medical Oncology; FACS=fluorescence-activated cell sorting; FISH=fluorescence *in situ* hybridisation; LDH=lactate dehydrogenase; NHL=non-Hodgkin lymphoma; PET=positron emission tomography; SUV=standardised uptake value; WBC=white blood cell; WHO=World Health Organization.

This site has been developed by Janssen-Cilag International NV. Janssen-Cilag International NV is the responsible editor of this document.

References

[1] National Organization for Rare Disorders 2021. Rare disease database: mantle cell lymphoma. Accessed April 2021. https://rarediseases.org/rare-diseases/mantle-cell-lymphoma/
[2] Dreyling M, *et al.* Newly diagnosed and relapsed mantle cell lymphoma: ESMO Clinical Practice Guidelines for diagnosis, treatment and follow-up. *Ann Oncol.* 2017;28(S4):iv62–iv71.
[3] Jain P, Wang M. Mantle cell lymphoma: 2019 update on the diagnosis, pathogenesis, prognostication, and management. *Am J Hematol.* 2019;94:710–725.
[4] Vose J. Mantle cell lymphoma: 2017 update on diagnosis, risk-stratification, and clinical management. *Am J Hematol.* 2017;92:806–813.
[5] Hoster E, *et al.* A new prognostic index (MIPI) for patients with advanced-stage mantle cell lymphoma. *Blood.* 2008;111(2):558–565.
[6] Cortelazzo S, *et al.* Mantle cell lymphoma. *Crit Rev Oncol Hematol.* 2012;82(1):78–101.
[7] McKay P, *et al.* A British Society for haematology good practice paper on the diagnosis and investigation of patients with mantle cell lymphoma. *Br J Haematol.* 2018;182:63–70.
[8] Scholzen T, Gerdes J. The Ki-67 protein: From the known and the unknown. *J Cell Physiol.* 2000;182(3):311–322.
[9] Tiemann M, *et al.* Histopathology, cell proliferation indices and clinical outcome in 304 patients with mantle cell lymphoma (MCL): a clinicopathological study from the European MCL Network. *Br J Haematol.* 2005;131(1):29–38.
[10] Hoster E, *et al.* Prognostic value of Ki-67 index, cytology, and growth pattern in mantle-cell lymphoma: results from randomized trials of the European Mantle Cell Lymphoma Network. *J Clin Oncol.* 2016;34:1386–1394.
[11] Eskelund CW. TP53 mutations identify younger mantle cell lymphoma patients who do not benefit from intensive chemoimmunotherapy. *Blood.* 2017;130(1):1903–1910.
[12] Swerdlow SH, *et al.* The 2016 revision of the World Health Organization classification of lymphoid neoplasms. *Blood.* 2016;127(20):2375–2390.
[13] Richard P, *et al.* "In situ-like" mantle cell lymphoma: a report of two cases. *J Clin Pathol.* 2006;59(9):995–996.
[14] Carvajal-Cuenca A, *et al.* In situ mantle cell lymphoma: clinical implications of an incidental finding with indolent clinical behavior. *Haematologica.* 2012;97(2):270–278.
[15] Rule S. The modern approach to mantle cell lymphoma. *Hematol Oncol.* 2019;37(S1):66–69.
[16] Aqil B, *et al.* Immunophenotypic variations in mantle cell lymphoma and their impact on clinical behavior and outcome. *Arch Pathol Lab Med.* 2018;142(10):1268–1274.

ITEM CODE: CP-233134 | DATE OF PREPARATION: June 2021

© Janssen Pharmaceutica 2021. This site is published by Janssen Pharmaceuticals. it is intended for healthcare professional audience only.